J BONE ONCOL 49 (2024) 100648

Contents lists available at ScienceDirect

Journal of Bone Oncology

journal homepage: www.elsevier.com/locate/jbo

Research Paper

Auxiliary diagnosis of primary bone tumors based on Machine learning model

Sandong Deng [a], Yugang Huang [b], Cong Li [c], Jun Qian [a,*], Xiangdong Wang [d,*]

[a] Department of Orthopedics, Affiliated Hengyang Hospital, Hunan Normal University (Hengyang Central Hospital), Hengyang, Hunan 421001, China
[b] Department of Radiology, Qianhai Life Insurance Guangzhou General Hospital, Guangzhou, Guangdong 511300, China
[c] School of Computer Science, Central South University, Changsha, Hunan 410083, China
[d] Hengyang Maternal and Child Health Hospital, Hengyang, Hunan 421001, China

HIGHLIGHTS

- DCNN model achieved 99.8% accuracy, 100% PPV, 99.6% NPV.
- 91.9% PPV distinguishes benign, malignant tumors; AUC is 0.62.
- Comprehensive WSI database enhances model's diagnostic capabilities.
- Performance matches senior pathologists, aiding accurate tumor diagnosis.
- Early diagnosis prevents metastasis, improves outcomes via AI integration.

ARTICLE INFO

Keywords:
Bone tumors
Artificial intelligence
Machine learning
Lesion detection
Auxiliary diagnosis

ABSTRACT

Objective: Research on auxiliary diagnosis of primary bone tumors can enhance diagnostic accuracy, facilitate early detection, and enable personalized treatment, thereby reducing misdiagnosis and missed cases, ultimately leading to improved patient prognosis and survival rates. In this study, we established a whole slide imaging (WSI) database comprising histopathological samples from all categories of bone tumors and integrated multiple neural network architectures for machine learning models. We then evaluated the accuracy of these models in diagnosing primary bone tumors.

Methods: In this paper, the machine learning model based on the deep convolutional neural network (DC-NN) method was combined with imaging omics analysis to analyze and discuss its clinical value in diagnosing primary bone tumors. In addition, this paper proposed a screening method for differentially expressed genes. Based on the paired T-test method, the process first estimated the tumor purity in the experimental data of each sample case, then assessed the actual gene expression value of the experimental data of each sample case, and finally calculated the optimized paired T-test statistics, and screened differentially expressed genes according to the threshold value.

Results: The selected model demonstrated excellent diagnostic accuracy in distinguishing between normal and tumor images, with overall accuracy of (99.8 ± 0.4) % for five rounds of testing using the DCNN model and positive and negative predictive values of (100.0 ± 0.0) % and (99.6 ± 0.8) %, respectively. The mean area under each dataset's curve (AUC) was (0.998 ± 0.004). Further, ten rounds of testing using the DCNN model showed an overall accuracy of (71.2 ± 1.6) % and a substantial positive predictive value of (91.9 ± 8.5) % in distinguishing benign from malignant bone tumors, with an average AUC of (0.62 ± 0.06) across datasets.

Conclusion: The deep learning model accurately classifies bone tumor histopathology based on the degree of infiltration, achieving diagnostic performance comparable to that of senior pathologists. These findings affirm the feasibility and effectiveness of histopathological diagnosis in bone tumors, providing a theoretical foundation for the application and advancement of machine learning-assisted histopathological diagnosis in this field.

* Corresponding authors.
E-mail addresses: qianjunyz1@163.com (J. Qian), wxd197366@163.com (X. Wang).

https://doi.org/10.1016/j.jbo.2024.100648
Received 10 June 2024; Received in revised form 2 November 2024; Accepted 3 November 2024
Available online 9 November 2024
2212-1374/© 2024 The Authors. Published by Elsevier GmbH. This is an open access article under the CC BY-NC-ND license (http://creativecommons.org/licenses/by-nc-nd/4.0/).

1. Introduction

In recent years, cancer has posed increasingly severe challenges to human health. With the accumulation of medical data and breakthrough developments in artificial intelligence technology, efficiently assisting in tumor diagnosis has become challenging for bioinformatics and computer disciplines. Primary bone tumors constitute only 0.2 % of human tumors, with an annual incidence of approximately 20 cases per million population [1]. These tumors often inflict damage to bone structure, leading to long-term dysfunction and diminished quality of life [2,3]. Currently, multimodal therapy, incorporating adjuvant chemotherapy and limb salvage surgery, is regarded as the standard treatment for most respectable primary bone tumors like osteosarcoma and Ewing's sarcoma. Adjuvant chemotherapy and targeted therapy also offer therapeutic benefits for some instances of unresectable tumors [4,5]. Early detection and diagnosis of malignant bone tumors are crucial to prevent distant metastasis and enhance patients' limb preservation rate, survival rate, and quality of life. X-ray imaging remains the most commonly utilized imaging tool for diagnosing primary bone tumors [6,7].

However, due to the low incidence of primary bone tumors, the complexity of histological subtypes, and the diversity of imaging features, the accuracy of plain film diagnosis is limited, and newer but more expensive techniques such as CT and MRI are usually needed to confirm suspected lesions seen on plain film [8]. The limited knowledge of primary doctors in X-ray image interpretation of bone tumors is a common factor causing misdiagnosis and delayed diagnosis of bone tumors [9]. Improving the diagnostic accuracy of screening X-ray images is crucial for early detection or exclusion of primary bone tumors. Diagnosing bone tumors is the first step in the medical management of patients, and it is of great value to guide the treatment plan. Early and correct diagnosis can provide timely intervention for lesions, which not only eases the progression of the disease and reduces the probability of tumor spread and metastasis but also improves the overall survival rate of patients and reduces the physical and mental pain and economic burden of patients [9]. Missed diagnosis or misdiagnosis may cause patients to miss the best treatment opportunity, which seriously affects the quality of life and prognosis [10].

The diagnostic criteria for bone tumors include:

1) Epidemiological characteristics, such as age, sex, and location of the disease;
2) Symptoms: including pain, swelling, pathological fractures, etc;
3) Signs such as tenderness, vein irritation, and elevated skin temperature;
4) Imaging examinations: identifying features such as lesion site, osteolytic transformation, invasive growth, periosteal reaction, etc., with specific findings such as a hardened area in CT scans, soft tissue infiltration, and high signal intensity in MRI scans, and increased radioactive uptake in radionuclide bone imaging;
5) Gross morphology of the tumor: considering its shape, color, texture, size, etc;
6) Assistive technologies, including immunohistochemistry, electron microscope scanning, special staining, flow cytometry, karyotype analysis, and protein/gene detection.

However, traditional diagnostic methods such as medical history and imaging have limitations. For example, while epidemiological indicators can effectively identify individual tumors, most bone tumors tend to have a trend of onset at a young age, a preference for males, and diverse incidence sites. Similarly, symptoms and signs of tumors are often similar and nonspecific, with most benign tumors displaying hidden growth and most malignant tumors causing pain and swelling. Although imaging evaluation may identify specific features such as the "Codman triangle" indicating osteosarcoma or cartilage cap protrusion indicating osteochondroma, many tumors, particularly those with a low incidence of malignancy, lack typical imaging features, making reliance on imaging alone for diagnosis unreliable [19,20].

Histopathological diagnosis remains the gold standard for determining the biological nature of tumors. In clinical practice, histopathological examination involves lesion biopsy and qualitative tumor diagnosis conducted through multidisciplinary collaboration among orthopedic, imaging, and pathology physicians [21]. Therefore, accurate and reliable histopathological diagnosis is crucial for determining the appropriate treatment plan for bone tumors.

Artificial intelligence, such as machine learning, in the medical field is increasing rapidly [22]. Some recent image omics feature analyses can more effectively and accurately diagnose diseases, predict prognosis, and evaluate the potential efficacy of targeted therapy through DCNN [12]. For example, Olczak et al. [13] used five publicly available deep-learning networks as a diagnostic tool. They accurately diagnosed 83 % of fractures, comparable to the accuracy of experienced orthopedic surgeons. Fave et al. [14] designed a predictive model using imaging omics analysis. They demonstrated that CT image texture intensity measured at the end of radiotherapy could effectively distinguish between high and low-risk patients with stage III non-small cell lung cancer. In this study, we developed a machine learning model to evaluate its performance in diagnosing primary bone tumors around the knee joint. As reported below, we analyzed its ability to distinguish benign from malignant bone tumors.

2. Data and methods

2.1. General information

The clinical data of patients with primary bone tumors at distal femur, proximal tibia, or proximal fibula admitted to our hospital from March 2017 to December 2023 were retrospectively analyzed. Two experienced pathologists evaluated the biopsy or excised specimen and provided a histological tumor diagnosis. This study examined 50 patients with malignant tumors and 25 patients with benign tumors, and the orthography of various lesions was used before treatment. In addition, 75 fully confirmed orthographies of normal knee joints were extracted from the imaging system of our hospital as normal controls, and there was no difference in gender between the three groups of subjects ($P > 0.05$), as shown in Table 1.

This study extracted the image in DICOM format and then converted it to JPEG format for further analysis.

2.2. Influence pretreatment and experimental design

Firstly, the data set was preprocessed, and 130 X-ray images were divided into the training and test sets. Because of the different brightness of the images, the X-ray images are converted into gray images before extracting the features. DCNN has achieved great success in image classification in many fields [15–17]. Compared with support vector machines, DCNN can automatically extract image features [18]. This study used a 34-layer depth residual network (ResNet34) to automatically extract and classify multiple features from X-ray images [19]. The advantage of ResNet is the use of residual blocks to solve the problem of network degradation caused by increasing network depth. The features extracted from the shallow layer are transmitted to the deep layer through the residual block, as shown in Fig. 1.

2.3. Statistical method

SPSS22.0 was used for statistical analysis of the obtained data. Measurement data were expressed with ($\bar{x} \pm s$) and compared with the *t*-test. Statistical data were expressed as rates. The comparison was performed using two tests. Analysis of variance was used for multi-group comparison. ROC curve was used to explore the clinical value of DCNN in diagnosing primary bone tumors around the knee joint.

Table 1
General information of three groups of subjects.

General data		Malignant tumor (n = 50)	Benign tumor (n = 25)	Normal (n = 75)	x^2 /F	*P*
Age(years)		25.5 ± 14.7	29.4 ± 16.3	35.1 ± 15.6	16.231	0.000
Gender	Male	24(48.9 %)	13(50.6 %)	35(46.9 %)	1.435	0.076
	Female	26(51.1 %)	12(49.5 %)	40(53.1 %)		
Position	Distal femur	28(50.6 %)	29(36.3 %)		5.832	0.000
	Proximal tibia	24(42.2 %)	43(53.8 %)			
	Proximal fibula	4(7.2 %)	8(10.0 %)			
Pathological type		Osteosarcoma 133(73.9 %)	Giant cell tumor 36(45.0 %)		6.213	0.000
		Chondrosarcoma 20(11.1 %)	Non ossifying fibroma 15(18.8 %)			
		Ewing sarcoma 5(2.8 %)	Chondroma 10(12.5 %)			
		Other 22(12.2 %)	Other 19(23.8 %)			

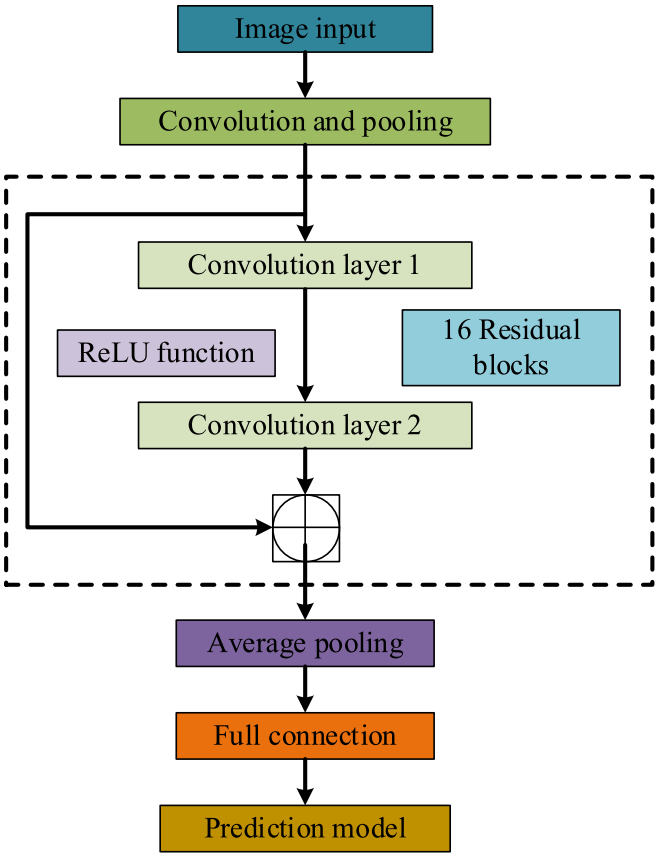

Fig. 1. Feature extraction and prediction flow chart of the DCNN method.

3. Results

3.1. Representative X-ray images of the knee joint and radiographs of benign and malignant tumors

130 positive images of the knee, including 130 "normal images" without bone tumors and 130 "tumor images" with bone tumors, were randomly divided into five groups. Each group comprised 52 standard images (Fig. 2a) and 52 tumor images. Each group of 52 tumor images included 36 malignant (Fig. 2b-d) and 16 benign (Fig. 2e-g) tumor images.

3.2. DCNN model diagnosed bone tumors

Five rounds of tests were conducted using the DCNN model to evaluate the model's ability to differentiate between "normal images" and "tumor images" to test its efficacy in bone tumor diagnosis. While each group is used as the test set, the other four groups are used as the training set. Finally, five different diagnostic accuracy values were obtained. The DCNN classifier is highly accurate, with four out of five tests showing 100 % accuracy in bone tumor diagnosis. Only one standard image from one round of tests was misdiagnosed. The overall accuracy was (99.8 ± 0.3) %, while the positive predictive value and negative predictive value were (100.0 ± 0.0) % and (99.7 ± 0.5) %, respectively, as shown in Table 2. In addition to accuracy, this study also uses AUC as a performance measure for machine learning. The AUC of each dataset was 0.99 (95 % confidence interval, 0.981–1.000), 1.00 (95 % confidence interval, 1.000–1.000), 1.00 (95 % confidence interval, 1.000–1.000), 1.0 (95 % confidence interval, 1.000–1.000), respectively. 1.000–1.000) and 1.0 (95 % confidence interval, 1.000–1.000) with a mean AUC of (0.998 ± 0.004), as shown in Fig. 3.

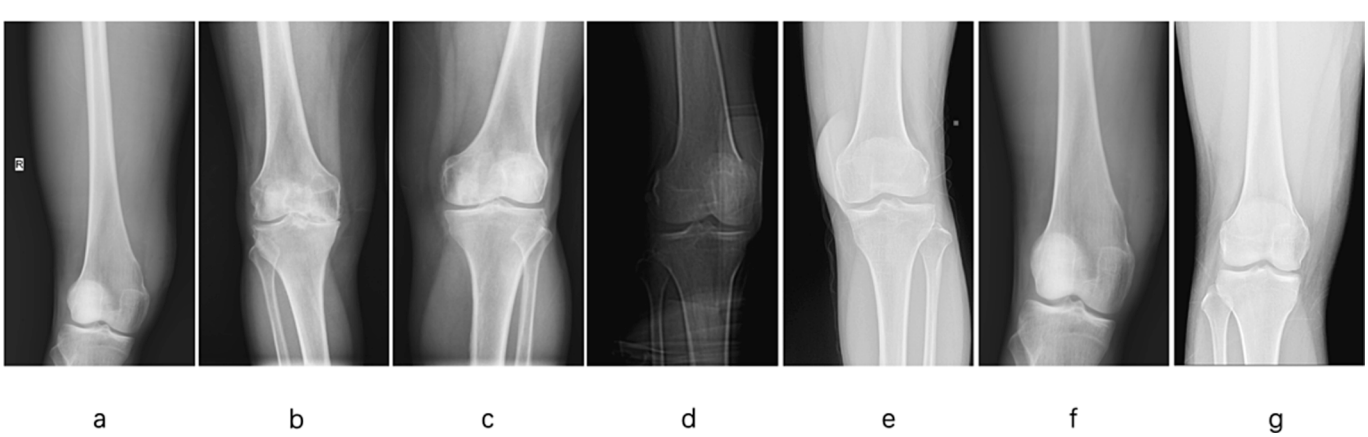

Fig. 2. The DCNN method is used for ROC curves to diagnose *peri*-knee bone tumors.

Table 2
Results of DCNN in the diagnosis of bone tumor.

Five rounds of testing	Positive predictive value (%)	Negative predictive value (%)	Overall accuracy (%)
1	100.0	98.5	99.2
2	100.0	100.0	100.0
3	100.0	100.0	100.0
4	100.0	100.0	100.0
5	100.0	100.0	100.0
Summary	100.0 ± 0.0	99.7 ± 0.5	99.8 ± 0.3

3.3. DCNN model distinguished benign and malignant tumors

This study evaluated the ability of DCNN to distinguish between benign and malignant tumors. Each group included 36 images of malignant and 16 of benign tumors. In each test round, 3 of the five groups are assigned as the training data set, while the other two groups are assigned as the test data set. 10 rounds (C25 = 10) of testing were conducted using the DCNN model, and the results are shown in Table 3. The overall accuracy was (71.2 ± 1.6) %, achieving a substantial positive predictive value (91.9 ± 8.5 %) in distinguishing benign from malignant bone tumors, and the mean AUC was (0.62 ± 0.06), as shown in Table 3.

3.4. Validation of simulation algorithm based on matching characteristics of tumor purity information

To evaluate the performance of the paired feature selection method proposed in this chapter in screening differentially expressed genes, four commonly used paired feature selection methods were selected in the experiment for comparison with the method used in this paper, namely, the paired T-test method (P-test) [5] and the paired T-test method based on multiple changes proposed by Cao et al. [9], write it as C-test; The modified version of the paired T-test method proposed by Tan et al. [17] is denoted as T-test. The combined method of Tanetal and Caoetal [12] is denoted as the TC test. The technique used in this article is labeled Test.

The main design idea of the experiment is as follows: First, the actual differentially expressed genes (i.e., tDEG genes) are determined, the number of tDEG genes is known when constructing the simulation data set, and the tDEG genes are sorted in descending order according to the Δ value of genes; Then, the predicted differentially expressed genes (i.e., pDEG genes) were calculated, and pDEG genes were screened out in the simulated data set using the paired feature selection method, and sorted in ascending order according to the p-value of the hypothesis test. Finally, according to the two sorted tDEG gene lists and pDEG gene lists, the first m genes were selected each time to calculate the screening accuracy and recall rate, where m values ranged from 1 to N to draw a P-R curve. When the value of m is more significant than M, there is no differential expression of genes in the simulated data set, and the P-R curve remains unchanged. Therefore, only 10 % of the total number of genes are considered in the P-R curve drawing (in the simulation experiment, M is set to 10 % of N). This is also why the highest recall rate on the P-R curve in the experimental results is only 0.1. Figure A-D is a comparison of P-R curves of Scenarios1, 2, 3, and 4 SCENARIos1, respectively, in which the X-axis indicates the recall rate, the Y-axis indicates the accuracy, and different colors of curves reflect different experimental results of the matching feature selection methods. Since only 10 % of the total number of genes are considered in the calculation of P-R curves, these are partial, with a maximum recall rate of 0.1.

Four commonly used paired feature selection methods were compared on four sets of simulation data, and the experimental results are shown in Fig. 3. Experimental results show that the method in this chapter has the maximum P-R area under the curve and is stable in four simulation data sets, and has strong robustness. According to the results, 24, 49, and 74 tDEG genes are predicted among the first 25, 50, and 75 pDEG genes in the Scenarios1 dataset, respectively, and the accuracy rates of SCENARIOS1 dataset are 96 %, 98 %, and 98.7 %, respectively,

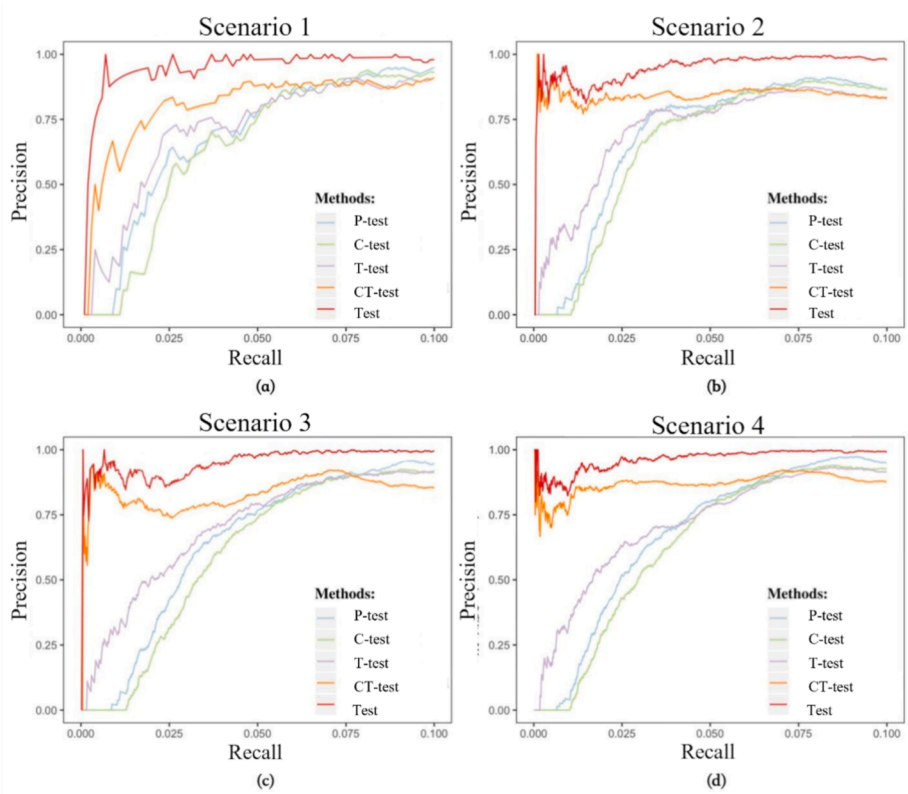

Fig. 3. Experimental results of the simulated data set.

Table 3
Results of DCNN in differentiating benign and malignant tumors around the knee joint.

Ten rounds of testing	Accuracy		ROC	
	Positive predictive value(%)	Negative predictive value(%)	Overall accuracy (%)	AUC(95 %CI)
1	100.0	0.0	68.8	0.62 (0.483–0.715)
2	92.8	21.8	71.3	0.62 (0.526–0.719)
3	97.7	10.5	69.7	0.59 (0.496–0.687)
4	70.6	58.5	69.5	0.65 (0.598–0.726)
5	93.9	21.9	70.7	0.55 (0.523–0.706)
6	86.7	32.5	72.9	0.63 (0.534–0.739)
7	89.6	14.7	75.4	0.58 (0.427–0.645)
8	97.2	15.3	72.1	0.54 (0.604–0.728)
9	90.6	32.3	71.8	0.70 (0.535–0.820)
10	95.7	34.5	72.2	0.67 (0.533–0.735)
Summary	91.5 ± 8.3	21.5 ± 15.4	71.5 ± 1.8	0.61 ± 0.03

which is the highest proportion of correct differentially expressed genes predicted. The first 125, 250, and 375 pDEG genes predicted in the Scenarios2 dataset are 111, 246, and 372, respectively. Chapter 4 ScenariOS2 ScenariOS2 matching feature selection method based on tumor purity information indicates a correct prediction rate of tDEG genes of 88.8 %, 98.4 %, and 99.2 %, respectively. Of all the methods, the proportion of differentially expressed genes predicted correctly was the highest. The same experimental phenomenon can be found in Scenarios3 and Scenarios4 datasets. Therefore, these experimental results indicate that the method proposed in this chapter has a more vital ability to predict tDEG, and the genes screened by it have a higher accuracy than other methods.

4. Discuss

Bone tumor is a disease with high incidence in adolescents. Malignant bone tumors often have a high mortality; early detection and early treatment are the key points to treat bone tumors. However, due to the limitations of medical treatment, many patients cannot be diagnosed in time, thus missing the best opportunity to treat bone tumors. In this paper, machine learning is used to study the diagnosis of bone tumors, and two algorithms are mainly proposed. The first is a model training algorithm based on sample information measurement, and the second is a bone tumor diagnosis algorithm based on multi-feature fusion.

This study showcased the high accuracy of a newly developed machine-learning model in diagnosing bone tumors by analyzing image-omics features. Subsequently, it assessed the model's efficacy in differentiating between benign and malignant bone tumors. Most primary care facilities can readily and affordably provide X-ray images, which hold significant value in screening for bone lesions. There has been debate regarding the number of images necessary for imaging omics research. Previous studies have demonstrated that moderate diagnostic accuracy or predictive value can be achieved through machine learning using tens or even hundreds of CT or MR images. However, more robust results are anticipated with an expanded sample size, reaching thousands or even tens of thousands of images. A smaller sample size can be acceptable, particularly for rare diseases like primary bone tumors, if the detection accuracy is high. Despite the inclusion of only 130 images in this study, the DCNN model achieved remarkable accuracy (>99 %) in distinguishing bone tumor images from standard X-ray images.

The model did not demonstrate the ability to accurately distinguish between benign and malignant bone tumors in the 130 images studied, which may be due to significant imaging differences within the benign or malignant bone tumor groups. However, the DCNN method can produce a high positive predictive value, which indicates that the probability of missing malignant lesions during screening is low, and further tests such as CT, MR, And biopsy can be guided accordingly. In this way, the method can guide clinical decision management.

AUC is a crucial indicator for evaluating the efficacy of machine learning models, but due to different goals, this indicator varies significantly among various clinical studies [24–26]. Regarding diagnostic use, the best AUC results should be superior to or equal to those of experts in the field of study. Otherwise, they may not be suitable for clinical use. An AUC slightly below the expert level may be acceptable when screening a large number of images, which may reduce the labor intensity of the imageologist. In predictive use, a minimum AUC of about 60–70 % is required to justify the medium predictive value of a machine learning model [27]. In this study, although the DCNN model achieved perfect accuracy in diagnosing bone tumors based on X-ray images, this model had a low negative predictive value in distinguishing benign from malignant bone tumors. The machine learning model may need help to complete the task because only a few dozen objects are included in each training set. Accuracy may be higher if more images are added and included in the training set.

The predictive value that defines whether a test has clinical application value varies in different clinical situations. Regarding comparing standard and bone tumor images, doctors need high positive and negative predictive values; only in this way can the radiologist not miss any patients with tumors and not cause too many unnecessary further tests [28–30]. The ideal detection characteristics may be more nuanced when comparing benign and malignant tumors, depending on how imaging results guide clinical practice. For instance, a bone oncologist conducting a biopsy for suspected malignancies aims to avoid missing any malignancies. In such cases, the oncologist prioritizes a model with a high positive predictive value, prioritizing sensitivity over specificity. Therefore, when assessing the suitability of a model for clinical use, overall accuracy is not the sole factor physicians consider.

This paper still needs to explore some problems in studying bone tumors. The following two points are mainly important: the first is that the accuracy of benign and malignant bone tumor detection needs to be improved; the second is that the information measurement algorithm can be further optimized and adapted. At present, the identification of bone tumors has achieved a very high accuracy rate, and the identification accuracy rate of benign and malignant is also of practical significance for diagnosing actual conditions. In addition to the problem of insufficient sample size, there is also the problem of a finer division of bone tumor types that needs to be addressed. As there are dozens of benign and malignant bone tumors, more in-depth studies may be required on different types of bone tumors to solve the problem of low accuracy in classifying benign and malignant bone tumors. Such research requires a large sample size and the assistance of professional doctors.

For model training algorithms, there may be more efficient information measurement methods in sample selection, which requires more in-depth research on the distribution of data sets, or a measurement method that can automatically adapt to different data sets of information can be found [31]. The method proposed in this paper needs to adjust the weights of average information entropy and standard deviation. In the future, the network may need to automatically adjust the weights to achieve a more efficient and accurate model training algorithm.

5. Conclusion

This paper evaluated the machine learning model using K-fold cross-

validation, where the images were evenly divided into five sets. Each dataset served as a test set in turn, while the remaining four sets were combined as a training set for each computational cycle. The bone tumor images were evenly distributed into five sets for both the benign and malignant models. Two of the five sets were chosen as the test set, while the remaining three were merged as the training set. Although intricate, this method allows for the application of imaging omics analysis in studying rare diseases, such as primary bone tumors, even with limited sample sizes. It effectively mitigates discrepancies between dataset groups and enhances test reproducibility. This approach to grouping may aid in constructing machine learning models for rare diseases, where collecting sufficient samples for study may take a considerable amount of time.

In summary, using machine learning, the image omics analysis of X-ray images is an effective and valuable method for bone tumor diagnosis. The DCNN method has not demonstrated the ability to distinguish between benign and malignant tumors accurately, but its high positive predictive value contributes to its clinical application. In future work, we will conduct prospective randomized controlled trials to evaluate the clinical application of machine learning models in the early diagnosis of primary healthcare bone tumors.

Ethical approval

All subjects in this study gave written consent to participate in our study.

CRediT authorship contribution statement

Sandong Deng: Writing – review & editing, Writing – original draft, Project administration, Formal analysis, Data curation, Conceptualization. **Yugang Huang:** Data curation, Resources, Supervision, Validation, Visualization. **Cong Li:** Validation, Software, Formal analysis. **Jun Qian:** Funding acquisition, Investigation, Project administration, Resources. **Xiangdong Wang:** Formal analysis, Funding acquisition, Project administration, Writing – review & editing.

Funding

This research article did not receive any external funding.

Declaration of competing interest

The authors declare that they have no known competing financial interests or personal relationships that could have appeared to influence the work reported in this paper.

Data availability

Data will be made available on request.

The supporting data for this study are available from the corresponding correspondence and the authors upon request.

References

[1] G. Lee, H.Y. Lee, E.S. Ko, et al., Radiomics and imaging genomics in precision medicine, Precis. Future Med. 1 (1) (2017) 10–31.
[2] M. Mullard, M. Cadé, S. Morice, et al., Sonic hedgehog signature in pediatric primary bone tumors: effects of the GLI antagonist GANT61 on ewing's sarcoma tumor growth, Cancers 12 (11) (2020) 3438.
[3] M. Davies, R. Lalam, K. Woertler, et al., Ten commandments for the diagnosis of bone tumors[C]//Seminars in Musculoskeletal Radiology, Thieme Medical Publishers 24 (03) (2020) 203–213.
[4] J. Talbot, M. Dupuy, S. Morice, et al., Antagonistic functions of connexin 43 during the development of primary or secondary bone tumors, Biomolecules 10 (9) (2020) 1240.
[5] P. Lambin, E. Rios-Velazquez, R. Leijenaar, et al., Radiomics: extracting more information from medical images using advanced feature analysis, Eur. J. Cancer 48 (4) (2012) 441–446.
[6] F.S. Stefanini, F.W.C. Gois, T.C.S.B. Arruda, et al., Primary bone lymphoma: pictorial essay, Radiologia Brasileira 53 (6) (2020) 419–423.
[7] C.N. Andreassen, L.M.H. Schack, L.V. Laursen, et al., Radiogenomics–current status, challenges and future directions, Cancer Lett. 382 (1) (2016) 127–136.
[8] D. Nascimento, G. Suchard, M. Hatem, et al., The role of magnetic resonance imaging in the evaluation of bone tumours and tumour-like lesions, Insights into Imaging 5 (2014) 419–440.
[9] Y. Liu, J. Kim, F. Qu, et al., CT features associated with epidermal growth factor receptor mutation status in patients with lung adenocarcinoma, Radiology 280 (1) (2016) 271–280.
[10] D.L. Shung, J.J.Y. Sung, Challenges of developing artificial intelligence-assisted tools for clinical medicine, J. Gastroenterol. Hepatol. 36 (2) (2021) 295–298.
[12] A. Ligocki, A. Jelinek, L. Zalud, et al., Fully automated dcnn-based thermal images annotation using neural network pretrained on rgb data, Sensors 21 (4) (2021) 1552.
[13] J. Olczak, N. Fahlberg, A. Maki, et al., Artificial intelligence for analyzing orthopedic trauma radiographs: deep learning algorithms—are they on par with humans for diagnosing fractures? Acta Orthopaedica 88 (6) (2017) 581–586.
[14] X. Fave, L. Zhang, J. Yang, et al., Delta-radiomics features for the prediction of patient outcomes in non–small cell lung cancer, Sci. Rep. 7 (1) (2017) 588.
[15] Y. Fan, L. Xi, D.S.T. Hughes, et al., MuSE: accounting for tumor heterogeneity using a sample-specific error model improves sensitivity and specificity in mutation calling from sequencing data, Genome Biol. 17 (2016) 1–11.
[16] A. McKenna, M. Hanna, E. Banks, et al., The Genome Analysis Toolkit: a MapReduce framework for analyzing next-generation DNA sequencing data, Genome Res. 20 (9) (2010) 1297–1303.
[17] D.E. Larson, C.C. Harris, K. Chen, et al., SomaticSniper: identification of somatic point mutations in whole genome sequencing data, Bioinformatics 28 (3) (2012) 311–317.
[18] D.C. Koboldt, Q. Zhang, D.E. Larson, et al., VarScan 2: somatic mutation and copy number alteration discovery in cancer by exome sequencing, Genome Res. 22 (3) (2012) 568–576.
[19] R.L. McDonald, S.M. Chilton, M.W. Jones-Lee, et al., Dread and latency impacts on a VSL for cancer risk reductions, J. Risk Uncertain. 52 (2) (2016) 137–161.
[20] J. Yu, Z. Shi, Y. Lian, et al., Noninvasive IDH1 mutation estimation based on a quantitative radiomics approach for grade II glioma, Eur. Radiol. 27 (2017) 3509–3522.
[21] T. Wang, K. Birsoy, N.W. Hughes, et al., Identification and characterization of essential genes in the human genome, Science 350 (6264) (2015) 1096–1101.
[22] A. Marusyk, K. Polyak, Tumor heterogeneity: causes and consequences, Biochim. et Biophys. Acta (BBA)-Rev. Cancer 1805 (1) (2010) 105–117.
[24] M.A. Mazurowski, J. Zhang, L.J. Grimm, et al., Radiogenomic analysis of breast cancer: luminal B molecular subtype is associated with enhancement dynamics at MR imaging, Radiology 273 (2) (2014) 365–372.
[25] P. Kesharwani, A.K. Iyer, Recent advances in dendrimer-based nanovectors for tumor-targeted drug and gene delivery, Drug Discov. Today 20 (5) (2015) 536–547.
[26] Q. Li, D. Zhao, X. Shao, et al., Aptamer-modified tetrahedral DNA nanostructure for tumor-targeted drug delivery, ACS Appl. Mater. Interfaces 9 (42) (2017) 36695–36701.
[27] A. Reiner, D. Yekutieli, Y. Benjamini, Identifying differentially expressed genes using false discovery rate controlling procedures, Bioinformatics 19 (3) (2003) 368–375.
[28] R.L. Somorjai, B. Dolenko, R. Baumgartner, Class prediction and discovery using gene microarray and proteomics mass spectroscopy data: curses, caveats, cautions, Bioinformatics 19 (12) (2003) 1484–1491.
[29] C. Trapnell, A. Roberts, L. Goff, et al., Differential gene and transcript expression analysis of RNA-seq experiments with TopHat and Cufflinks, Nat. Protoc. 7 (3) (2012) 562–578.
[30] M.D. Robinson, D.J. McCarthy, G.K. Smyth, edgeR: a Bioconductor package for differential expression analysis of digital gene expression data. Bioinformatics, 2010, 26(1): 139–140.
[31] C. Zhang, W. Cheng, X. Ren, et al., Tumor purity as an underlying key factor in glioma, Clin. Cancer Res. 23 (20) (2017) 6279–6291.

Further Reading

[11] J.A. Carrillo, A. Lai, P.L. Nghiemphu, et al., Relationship between tumor enhancement, edema, IDH1 mutational status, MGMT promoter methylation, and survival in glioblastoma, Am. J. Neuroradiol. 33 (7) (2012) 1349–1355.
[23] T. Abeel, T. Helleputte, Y. Van de Peer, et al., Robust biomarker identification for cancer diagnosis with ensemble feature selection methods, Bioinformatics 26 (3) (2010) 392–398.